



RESENTING CLINICAL SIGNS

History: Grade 3-4/6 left-sided murmur. Asymptomatic.

DATE

6/23/22

ECHOCARDIOGRAPHIC FINDINGS

2D, M-mode, and Doppler study.

PERFORMED BY:

Kelly Vazquez

There is mild left atrial dilation. The mitral valve leaflets are thickened and exhibit systolic prolapse. A mild to moderate jet of eccentric mitral regurgitation is present. There is mild left ventricular dilation. Left ventricular systolic function is normal. The aorta and aortic valve are normal. Right atrial and right ventricular dimensions are normal. The tricuspid valve is normal. The pulmonary artery and pulmonic valve are normal. No pericardial effusion or cardiac masses are seen.

INTERPRETED BY

Keith Blass, DVM,
MS, DACVIM
(Cardiology)

LA - 29.4 mm
LVIDd - 29.3 mm
LVIDs - 15.2 mm
FS - 48%
RA - 15.3 mm
LVOT - 1.36 m/s
RVOT - 0.87 m/s

PATIENT

Luna Mones

ASSESSMENT/RECOMMENDATIONS

Degenerative mitral valve disease

SPECIES

Canine

This examination demonstrates mild to moderate regurgitation of blood across Luna's mitral valve resulting from degenerative valve disease. Secondary to her regurgitation, Luna has mild dilation of both her left atrium and left ventricle, though her left ventricular systolic function is well-preserved. As only mild left heart chamber dilation is present, Luna's current risk for the development of clinical signs secondary to her disease, such as coughing, exercise intolerance, syncope, and labored breathing, appears to be relatively low, though careful monitoring for these signs is recommended going forward.

BREED

Toy Poodle Mix

I recommend starting Luna on pimobendan (2.5 mg BID), as this medication should help to slow the progression of her mitral valve disease.

SEX

FS

A recheck echocardiogram is recommended in 9 months. Thoracic radiographs are recommended if Luna experiences respiratory clinical signs.

AGE

8 y

WEIGHT

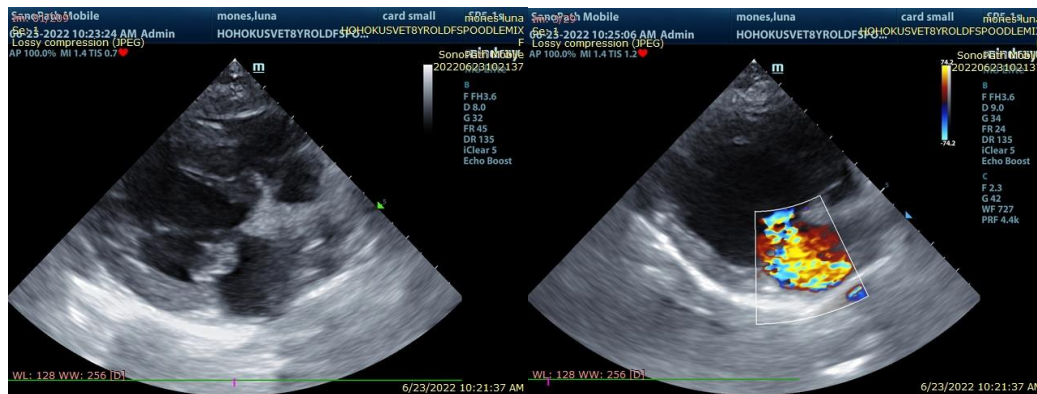
17 lb

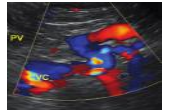
HOSPITAL NAME

Ho-Ho-Kus VH

REFERRING VET

Dr. Gannon





The information and recommendations provided are based on the images presented by the referring veterinarian. No evaluation can be communicated regarding pathology that was not visible in the image/video clips provided.

DATE

6/23/22

Thank you for this referral. If the clinical or image interpretation does not parallel your findings or if I can be of any further assistance please contact me.

PERFORMED BY:

Kelly Vazquez

Keith Blass, DVM, MS, DACVIM (Cardiology)
KeithBlass@gmail.com
631-804-5754

INTERPRETED BY

Keith Blass, DVM,
MS, DACVIM
(Cardiology)

PATIENT

Luna Mones

SPECIES

Canine

BREED

Toy Poodle Mix

SEX

FS

AGE

8 y

WEIGHT

17 lb

HOSPITAL NAME

Ho-Ho-Kus VH

REFERRING VET

Dr. Gannon